Audiogram Screening Protocols in Vestibular Schwannomas

Kiley Trott[a], Sean Maloney[b], Kyle Fisher[a,c], Brian McGettigan[a,c], Thomas Willcox[a]
[a] Department of Otolaryngology Head and Neck Surgery, Thomas Jefferson University, Philadelphia, PA
[b] Sidney Kimmel Medical College, Thomas Jefferson University, Philadelphia, PA
[c] Holy Redeemer Hospital, Jenkintown, PA

INTRODUCTION

Vestibular schwannomas are the most common tumors found in the cerebellopontine angle[1]. They are slow-growing, benign tumors that arise from Schwann cells lining the vestibular division of the eighth cranial nerve and classically present with asymmetric sensorineural hearing loss with or without tinnitus. Yet only 1-2% of patients with these classic symptoms are found to have vestibular schwannomas[2]. Magnetic Resonance Imaging (MRI) is the gold standard test for diagnosing vestibular schwannomas with sensitivity nearing 100 per cent and high specificity[3]. Given the high cost of MRI, several protocols have been developed to guide patient selection for MRI testing. The purpose of this study is to analyze screening audiogram protocols for predictive accuracy of vestibular schwannomas and describe appropriate guidelines for patient selection for MRI.

METHODS

A retrospective review of electronic medical records (EMR) identified 1353 patients with vestibular schwannomas treated between January 2000 and December 2014. Patients with charts inaccessible via EMR, masses identified on imaging prior to audiogram evaluation, radiographic reports without tumor laterality, and bilateral masses were excluded. The study group consisted of 538 patients with screening audiograms and follow up MRI. Audiograms and imaging reports from our institution and outside facilities were utilized. Nine previously published audiogram screening protocols were used to predict tumor laterality as confirmed by MRI. Sensitivity and specificity were calculated for each screening protocol.

Protocols Reported in Literature	
Protocol	Asymmetry of Thresholds
Department of Health	≥20 dB at any single frequency between 0.5 and 4 kHz
AAO-HNS	≥15 dB between average of 0.5, 1, 2 and 3 kHz
Oxford	≥15 dB between average of 0.5 to 8 kHz
Sunderland	≥20 dB at 2 neighboring frequencies
Nashville	≥15 dB at any single frequency between 0.5 and 4 kHz
Seattle	≥15 dB between the average of 1 and 8 kHz
Rule of 3000	≥15 dB at 3kHz
AMCLASS	≥10 dB at 2 or more frequencies; Or >15 dB at any single frequency
Cueva	≥15 dB at 2 or more frequencies; Or >15% difference between speech discrimination

Table 1. AAO-HNS, American Academy of Otolaryngology Head and Neck Surgery; AMCLASS, audiogram classification system

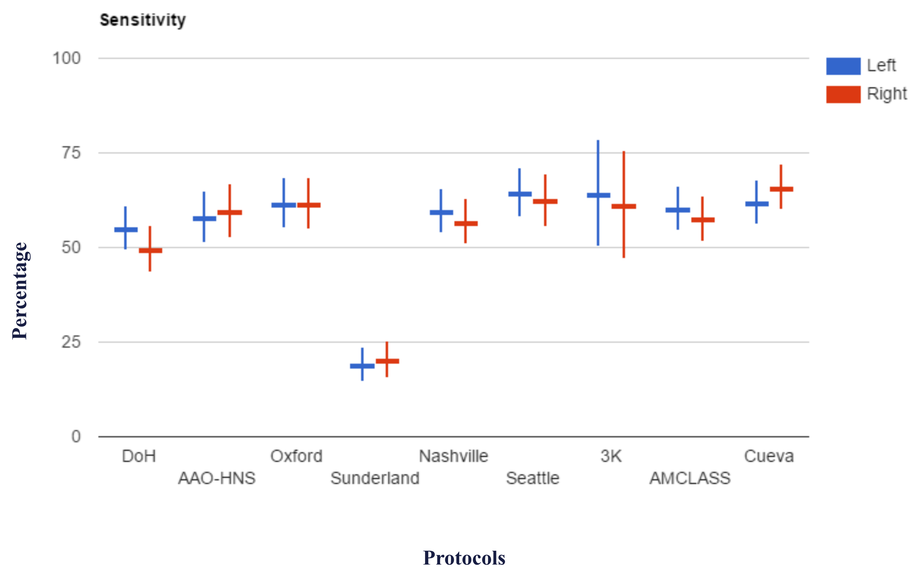

Figure 1. Mean specificity for each protocol with confidence intervals ranging from 5 to 95% for left and right ear.

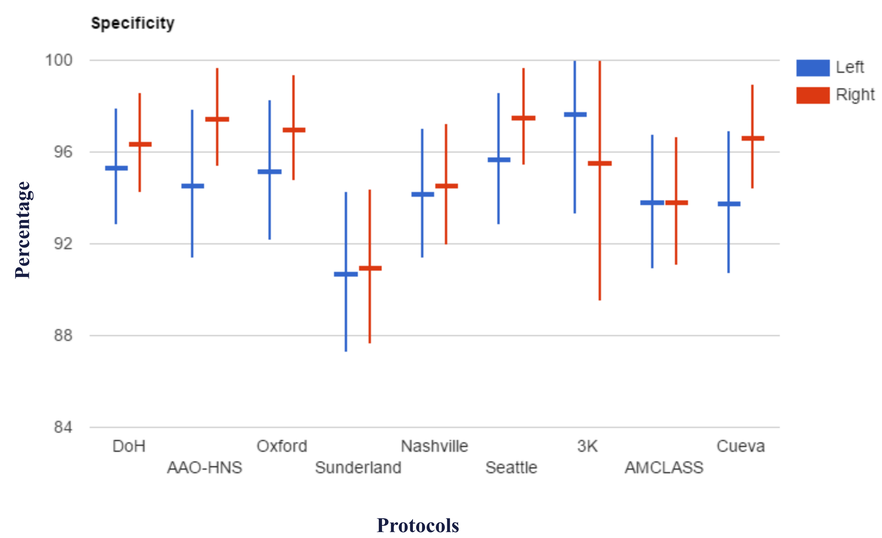

Figure 2. Mean sensitivity for each protocol with confidence intervals ranging from 5 to 95% for left and right ear.

RESULTS

Five protocols could only be performed on some patients (as few as 89, but up to 490) given insufficient audiogram data for a given protocol. Protocol sensitivity ranged from 19% to 64% and specificity ranged from 90% to 97%.

CONCLUSIONS

- All protocols were found to have a high degree of specificity and much lower degree of sensitivity.
- The Sunderland protocol had significantly lower sensitivity compared to all other protocols. The higher degree of hearing loss at multiple frequencies required for the protocol appears to be too stringent.
- While the high specificity across protocols would produce a low rate of false positives, the low sensitivities would produce a high rate of false negatives. An ideal screening protocol has high sensitivity so that there is a low rate of false negatives.
- Given the finding of low sensitivity across protocols, clinical judgment utilizing patient symptomatology in addition to audiometric findings is paramount for appropriately shepherding patients to confirmatory MRI testing.
- These findings suggest future studies are necessary to elucidate screening protocols with improved sensitivity.

REFERENCES

1. Hochberg F, Pruitt A. Neoplastic diseases of the central nervous system. In: Isselbacher ICJ, Braunwald E, Wilson JD, Martin JB, Franci AS, Kasper DL, eds. Harrison's Principles Of Internal Medicine. 13th ed., Chapter 369. New York: McGraw-Hill, 1994.
2. Obholzer RJ, Harcourt JP. Magnetic resonance imaging screening of vestibular schwannoma: analysis of published protocols. J Laryngol Otol 2004;118:329Y32.
3. Sidman J, Carrasco V, Whaley R, Pillsbury H. Gadolinium – the new gold standard for diagnosing cerebellopontine angle tumours. Arch Otolaryngol Head Neck Surg 1989;115:1244–7