Post-Operative Axial Imaging Can Predict Future Complications in Asymptomatic Osteocutaneous Free-Flap Patients

Swendseid B, Kumar A, Luginbuhl A, Krein H, Goldman R, Heffelfinger R, Curry J
Thomas Jefferson University Hospital, Sidney Kimmel Cancer Center

Introduction

- Free flap reconstruction is the gold standard for mandibular and maxillary defects.
- Late complications that develop after surgical healing has concluded can impart significant morbidity
- Osteonecrosis, chronic infection and fistula are often advanced when identified, necessitating further surgery or revision free flap.
- We sought to assess whether post-operative axial imaging could identify patients predisposed to developing late complications.

Methods

- Database review of free-flaps performed between 2007-2018
- 250 osteocutaneous free flaps identified
- 19 had underwent neo-condyle creation during free flap surgery
- 107 had post-operative axial imaging
- Univariate and multivariate analysis performed in consultation with statistician

Results

Bony Nonunion and Malunion

- 38% had radiographic nonunion
- 12% had radiographic partial nonunion
- Average of 0.8 malunion segments out of average of 2.8 bony appositions per patient
- Overall, 5% of appositions exhibited partial but incomplete union and 25% of exhibited nonunion
- Nonunion is predicted by cancer diagnosis (OR 3.18, p-0.035), hypertension (OR 2.25, p=0.047) and male gender (OR 2.32 p=0.049)

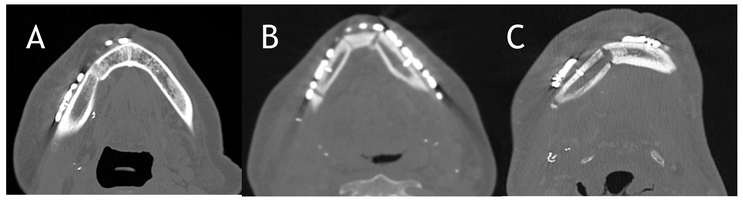

Figure 1-Post-operative CT scans showing appropriate bone segment fusion (A), partial/incomplete union (B) and nonunion (C) .

- Radiographic nonunion correlates with development of late complications (OR 2.91, CI 1.14-7.42, p = 0.026)
- Radiographic nonunion predicts late wound breakdown (OR 3.09, CI 1.08-8.81, p = 0.035)
- Radiographic nonunion predicts osteonecrosis (OR 5.08, CI 1.26-20.5, p = 0.022)

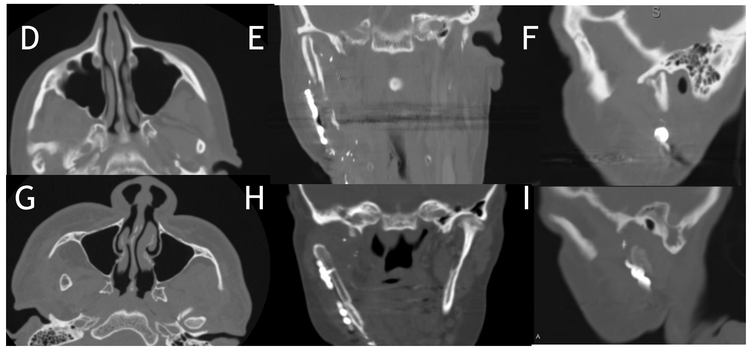

Figure 2-Neocondyles in near-anatomic position in axial (D), coronal (E) and sagittal (F) planes. Malpositioned neocondyles shown in G, H and I.

Results (Cont)

Neocondyle Position

- A neocondyle is created with one end of the osteocutaneous segment
  - Cadaveric cartilage cap covered with alloderm
  - Reconstruction is sutured to the remnant glenoid fossa
- Anteriorly displaced neocondyle >1 cm associated with jaw misalignment and clicking (57.1%, p = 0.031)
- Edentulous patients had no anterior displacement, but 43% of dentulous patients did
- Inferior displacement > 1cm associated with dysphagia (0.028)

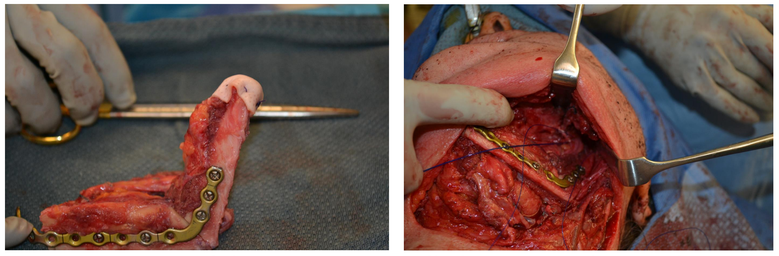

Figure 3-Neocondule creation using Alloderm cap and sutured to glenoid fossa

Conclusions

- Post-operative axial imaging can help predict complications in free flap patients
- Partial union or nonunion of bone segments is associated with wound breakdown and osteonecrosis
  - Encouraging fusion with bone chips, paste and perfect segment apposition may minimize complications
- Displacement of the neocondyle from the TMJ can predict dysphagia or jaw misalignment

References

Lodders, J. N., Schulten, E. a. J. M., de Visscher, J. G. a. M., Forouzanfar, T. & Karagozoglu, K. H. Complications and Risk after Mandibular Reconstruction with Fibular Free Flaps in Patients with Oral Squamous Cell Carcinoma: A Retrospective Cohort Study. *J Reconstr Microsurg* **32**, 455–463 (2016).
van Gemert, J. T. M. *et al.* Early and late complications in the reconstructed mandible with free fibula flaps. *Journal of Surgical Oncology* **117**, 773–780 (2018).
Zender, C. A., Mehta, V., Pittman, A. L., Feustel, P. J. & Jaber, J. J. Etiologic causes of late osteocutaneous free flap failures in oral cavity cancer reconstruction. *Laryngoscope* **122**, 1474–1479 (2012).
Day, K. E., Desmond, R., Magnuson, J. S., Carroll, W. R. & Rosenthal, E. L. Hardware removal after osseous free flap reconstruction. *Otolaryngol Head Neck Surg* **150**, 40–46 (2014).
Teng, M. & Futran, N. Osteoradionecrosis of the mandible. *Current Opinion in Otolaryngology & Head and Neck Surgery* **13**, 217–221 (2005).
Beumer, J., Harrison, R., Sanders, B. & Kurrasch, M. Osteoradionecrosis: predisposing factors and outcomes of therapy. *Head Neck Surg* **6**, 819–827 (1984).
Wood, C. B., Shinn, J. R., Amin, S. N., Rohde, S. L. & Sinard, R. J. Risk of plate removal in free flap reconstruction of the mandible. *Oral Oncol.* **83**, 91–95 (2018).