



Histoplasmosis of the Head and Neck in the Immunocompetent Patient

Ashley P. O'Connell Ferster MD¹; Aaron Jaworek MD², Amanda Hu MD, FRCSC²

¹Department of Surgery, Division of Otolaryngology-Head and Neck Surgery, The Pennsylvania State University, College of Medicine, Hershey, PA

²Department of Otolaryngology-Head & Neck Surgery, Drexel University College of Medicine, Philadelphia, PA

Introduction

Histoplasmosis is an infection caused by the fungus *Histoplasma capsulatum* and it typically affects the respiratory system¹. *H. capsulatum* is endemic in the Ohio and Mississippi River valleys, and 60-90% of those living in this region have been exposed to the fungus¹. Histoplasmosis is a disease of immunocompromised patients, with very few cases reported in immunocompetent patients.

Because of its paucity, few clinicians have the knowledge to diagnose Histoplasmosis, making risk of misdiagnosis high. Two case reports demonstrating head and neck manifestations of histoplasmosis in immunocompetent patients will be presented to help clinicians learn more about this disease.

Contact

Amanda Hu, MD, FRCSC
Otolaryngology – Head & Neck Surgery
Drexel University College of Medicine
Phone: 215-762-5530
Fax: 215-762-5540
Email: amandahu@phillyENT.com

Case Reports

Case #1

80-year-old male, retired farmer with prior smoking history presented with tender oral lesions, one on the dorsal tongue for six months and one on the floor of mouth for one month. He also had a 10-pound weight loss. Topical Nystatin showed no resolution of his lesions or symptoms.

His exam showed:

- a 2-cm deep, fissured ulceration at the midline dorsal tongue with rolled, smooth borders, minimal erythema, tender to palpation without exudate, bleeding, or surrounding vesicular lesions.
- a 1.5-cm lesion at the midline floor of mouth with rounded, rolled, smooth borders and several nearby granuloma-like papules.

Biopsy was positive for histoplasmosis. He was treated with oral itraconazole and his oral lesions resolved.

Case #2

57-year-old male, ex smoker, presented with sore throat, odynophagia, bilateral referred otalgia, hoarseness, increased mucous production, and a 45-50 pound weight loss over 6 months. Risk factors included recent trip to Peru and ownership of a parrot. Amoxicillin, steroids, and Nexium showed no resolution of symptoms. His exam showed:

- strained voice, no neck masses or lymphadenopathy.
- Figure 1 shows the laryngoscopy

Biopsy was positive for histoplasmosis. Patient was seen by infectious diseases and treated with oral ketaconazole for 3 weeks. His symptoms resolved.

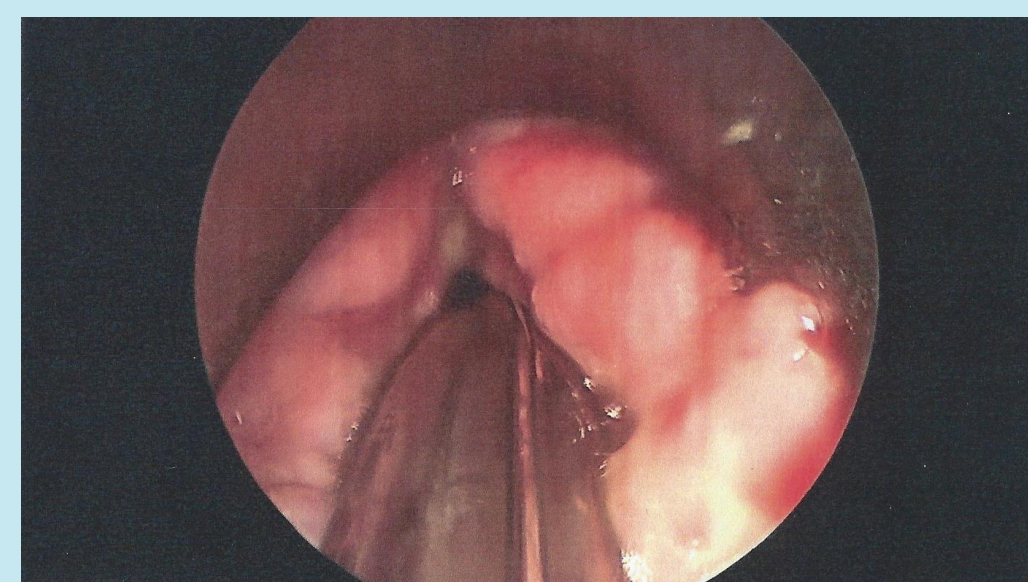
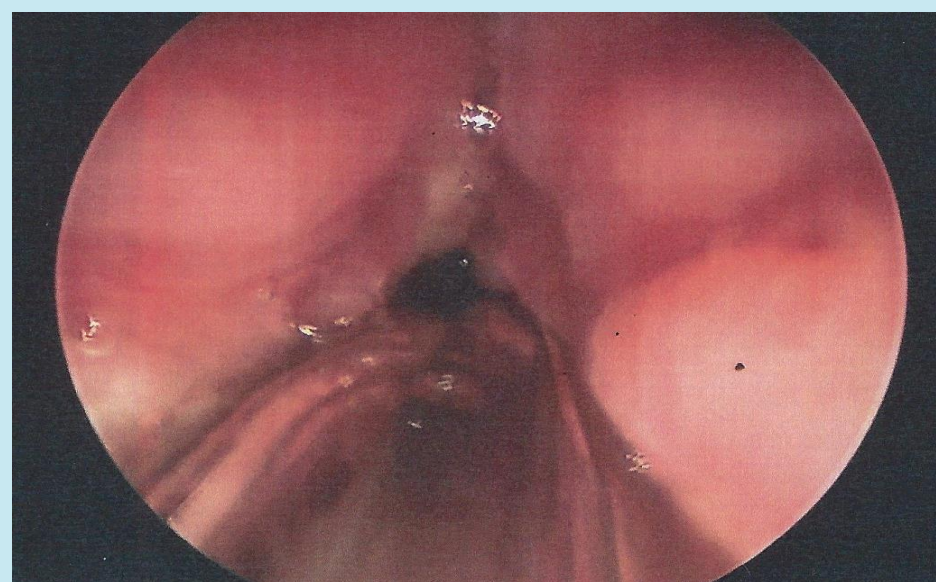


Figure 1. Laryngeal manifestations of histoplasmosis in the immunocompetent patient, revealing thickened, irregular mucosa of the vocal folds.

Discussion

Identification of Histoplasmosis can be made through tissue or culture revealing chronic, non-caseating granulomatous inflammation². Special stains, including Periodic acid-Schiff (PAS) and Gomori's methenamine-silver (GMS) are used to confirm the microorganism². Serum antigen testing and antibody testing via enzyme immunoassay (EIA) can also be used. Treatment includes oral conazoles for 3 to 4 weeks³. Other treatments include topical nystatin for 3 weeks, followed by oral conazoles³. Refractory cases may be treated with IV amphotericin B³.

Conclusion

Diagnosis of histoplasmosis can be difficult in light of the multiple lesions, both benign and malignant, that can occur in the head and neck. Clinicians must be aware of histoplasmosis as a possible etiology of head and neck lesions.

References

- ¹JW, Winthrop KL, et al. Geographic distribution of endemic fungal infections among older persons, United States. *Emerg Infect Dis*. 2011. 17(9): 1664-1669.
- ²Iqbal F, et al. Oral presentation of histoplasmosis in an immunocompetent patient: a diagnostic challenge. *Austr Dental J*. 2014; 59: 386-388.
- ³Mehanna HM, et al. Fungal laryngitis in immunocompetent patients. *J Laryngol and Otolaryngol*. 2004. 118: 379-381.