Accuracy of Chest X-ray for the Evaluation of Tracheostomy Tube Position in Infants

Allison Keane MD[1]; Robert Saadi MD[1]; Einat Slonimsky, MD[2]; Meghan Wilson, MD[1] ; Jason May, MD[1]
[1]Department of Otolaryngology – Head and Neck Surgery, The Pennsylvania State University, College of Medicine, Hershey, PA, USA
[2]Department of Radiology, The Pennsylvania State University, College of Medicine, Hershey, PA, USA

Background

The length of the pediatric airway ranges between 4.3-9 cm from vocal cords to carina in children less than 2 years of age[1-3]. Preterm neonatal airways are shorter. Fetal and neonatal tracheal length, measured from the inferior cricoid border to carina, has been measured as 1.5-4 cm in gestational ages 20-40 weeks, and has a strong linear relationship with gestational age[4,5]. Tracheal length has been shown to be affected by the patient's head position; neck extension lengthens the trachea and neck flexion shortens the trachea[6]. Unlike endotracheal tubes, the tracheostomy tube cannot be retracted or advanced to adjust positioning of the distal tip. As such, a patient's tracheostomy tube must be of appropriate length to maintain effective ventilation.

Chest X-rays are often obtained following pediatric tracheotomy to rule out complications and estimate the position of the distal tip of the tracheostomy tube. Clinical decisions regarding change in tracheostomy tube size can be based on chest X-rays. However, when evaluating the tracheostomy tube, the positioning of the patient, neck flexion/extension, and angle of the X-ray may alter the relative distance of the tracheostomy tube from the carina on chest radiograph[7,8]. The preferred method of assessing this distance is by direct visualization via fiberoptic tracheoscopy and measurement along the length of the scope.

Objective

Clinical experience suggests chest radiography and fiberoptic tracheoscopy measurements of tracheostomy tube position in infants do not demonstrate a high degree of correlation. The objective of this study is to compare measurements made on chest X-ray and fiberoptic tracheoscopy to evaluate this discrepancy. In the present study, we compare both measurement methods of tracheostomy tube positioning in pediatric patients under 1 year of age.

Methods

All cases of pediatric patients who underwent tracheotomy at less than 1 year of age from 2014-2019 were reviewed. Patients were included if they had both intraoperative measurement of tracheostomy tube position by tracheoscopy and postoperative chest X-ray within 24 hours of the procedure. Tracheostomy tube position was evaluated by the distance of the distal tip of the tracheostomy tube to the carina. Documented intraoperative findings were compared to measurements made on chest X-ray by an attending radiologist blinded to the intraoperative measurements.

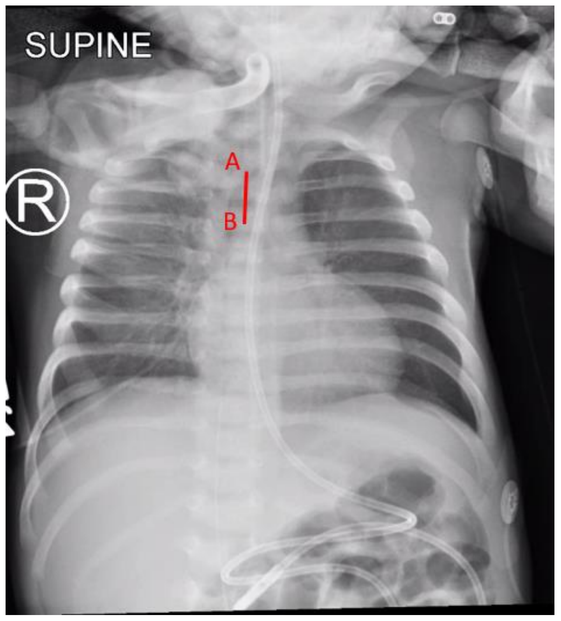

Figure 1: X-ray Measurement of Tracheostomy Tube Position
Figure 1 demonstrates a PA chest X-ray measurement of distance from the distal tracheostomy tube tip (A) to the carina (B).



Figure 2: Tracheoscopy Measurement Method
Figure 2a demonstrates marking the proximal scope when the distal scope is positioned at the carina
Figure 2b demonstrated marking the proximal scope when the distal scope is positioned at the distal tube tip
Figure 2c demonstrates measuring the distance from the distal tube tip (A) to the carina (B)

Results

The study included 66 patients; 30 patients had available data. The mean distance from the tracheostomy tube tip to the carina measured by tracheoscopy was 8.88 mm (range, 3.5-20 mm) and measured radiographically was 11.71 mm (range, 2.4-23.3 mm). The mean difference between the measurements was 2.82 mm (95% CI, 0.56-5.086). A paired t-test revealed t=2.55 (p-value, 0.016). Ninety percent of patients had measurements that differed by greater than 2 mm; 53% had measurements that differed by greater than 5 mm and 1% had measurements differing by greater than 10 mm.

Table 1: **Patient Information**
Table 1 includes demographic data for patients included in analysis.

Patient Information	Average (Range)
Gender	14 Male, 16 Female
Age on date of tracheotomy (days)	101.2 (16-286)
Length on day of tracheotomy (cm)	48 (21-67)
Weight on day of tracheotomy (kg)	3.91 (2.49-8.63)
Gestational age at birth (weeks)*	31.84 (23-40)
Birth weight (kg)*	1.97 (0.45-3.6)

Table 2: Individual Measurement Comparison
Table 2 provides the number of patients with differences in their tracheostomy tube measurements by mild (>2mm), moderate (>5mm) and severe (>10mm) amounts.

Measurement (mild)	# of Patients	Measurement (moderate)	# of Patients	Measurement (severe)	# of Patients
Measurements differing by >2 mm	27	Measurements differing by >5 mm	16	Measurements differing by >10 mm	3
X-ray - Tracheoscopy = >2 mm	19	X-ray - Tracheoscopy = >5 mm	12	X-ray - Tracheoscopy = >10 mm	3
Tracheoscopy - X-ray = >2 mm	8	Tracheoscopy - X-ray = >5 mm	4	Tracheoscopy - X-ray = >10 mm	0
Measurements differing by <2 mm	3	Measurements differing by <5 mm	14	Measurements differing by <10 mm	27

Discussion and Conclusions

Significant discrepancy exists between direct tracheoscopy and X-ray measurements of tracheostomy tube position in the infant population. Over 50% of our patients had measurements that differed by greater than 5 mm, which corresponds to a significant portion of tracheal length in infants less than 1 year of age. Measurements made on chest radiographs are imprecise and inconsistent when compared to tracheoscopy measurement of tracheostomy tube depth. Tracheostomy tubes vary in length by 1-2 mm and such large discrepancies in measurements could lead to selection of an inappropriate tracheostomy tube size. Clinical decisions regarding changes to tracheostomy tube sizes should mostly rely on tracheoscopy performed with the patient supine.

Contact

Allison Keane, MD
Department of Otolaryngology- Head and Neck Surgery
Pennsylvania State University Milton S. Hershey Medical Center
500 University Dr., Hershey, PA, 17033
Email: akeane@pennstatehealth.psu.edu
Phone: (717)-531-6822

References

1. Fiadjoe, J E, R O S Litman, J F Serber, P A Stricker, and C J Cote. 2019. "The pediatric airway." In *In A Practice of Anesthesia for Infants and Children*, 297-339. Philadelphia: Elsevier.
2. Sirisopana , M, C Saint-Martin, N N Wang, and J Manoukian. 2013. "Novel Measurements of the Length of the Subglottic Airway in Infants and Young Children." *Anesthesia & Analgesia* 117 (2): 462–470.
3. Fearon , B, and J S Whalen. 1967. "Tracheal dimensions in the living infant." *Ann Otol Rhinol Laryngol* 76: 965–74.
4. Fayoux, P, B Marciniak, L Devisme, and L Storme. 2008. "Prenatal and early postnatal morphogenesis and growth of human laryngotracheal structures." *J Anat* 213 (2): 86–92.
5. Dave, M H, M Kemper, A R Schmidt, C P Both, and M Weiss. 2019. "Pediatric airway dimensions - A summary and presentation of existing data." *Paediatr Anaesth* 782-289.
6. Jordi Ritz, E M, B S Von Ungern-Sternberg , and K Keller. 2008. "The impact of head position on the cuff and tube tip position of preformed oral tracheal tubes in young children." *Anaesthesia* 63: 604–9.
7. Olufolabi, A J, G A Charlton, and P M Spargo. 2004. "Effect of head posture on tracheal tube position in children." *Anaesthesia* 1069-1072.
8. Im, D D, P A Ross, J Hotz, and C J L Newth. 2019. "Evaluating the practice of repositioning endotracheal tubes in neonates and children based on radiographic location." *Pediatric Critical Care Medicine* 1-4