Frozen Sectioning as a Rapid and Accurate Tool for Diagnosing Acute Invasive Fungal Rhinosinusitis

Max Hennessy[2], Bartholomew White M.D.[1], Joshua I Warrick M.D.[1],
Sakeena Payne M.D.[2], John McGinn M.D.[2], and Henry Crist M.D.[1]
Departments of Pathology[1] and Otolaryngology[2], Penn State Hershey Medical Center, Hershey, PA

Objectives

1) Describe the use of a novel rapid 20 min periodic acid Schiff for Fungus (PASF) stain to obtain a fast and accurate diagnose of acute invasive fungal rhinosinusitis (AIFRS) on frozen section (PASF-fs).

2) Describe the importance of communication between surgeon and pathologist when utilizing frozen section as a means to diagnose AIFRS.

Introduction

AIFRS is a rare and aggressive opportunistic infection that occurs in immunocompromised patients. Early diagnosis and management of the disease is crucial due to its rapid progression and lethality. Even with the advent of new antifungal treatments, survival rates can be as low as 20-50%, and the hours spent determining a diagnosis and treatment plan can be the difference between life and death.

Permanent section analysis is the gold standard for confirming AIFRS following biopsy. However, it is a time consuming process, and reliance upon this to obtain a diagnosis delays treatment. FS is a particularly useful tool at the time of biopsy to obtain an early diagnosis. However, due to the inability to use fungus-specific stains such as methenamine silver on FS analysis, it has historically not been as sensitive as the permanent section diagnosis. Here we report the use of a novel rapid 20 min modified PASF stain for FS analysis of suspected AIFRS as a means to obtain a rapid and accurate diagnosis.

Selected Reference

Payne SJ, et al. *Acute Invasive Fungal Rhinosinusitis: A 15-Year Experience with 41 Patients*. Otolaryngology– Head and Neck Surgery 2016, Vol. 154(4) 759–764

Generously supported by the Penn State Pathology Research Award Program

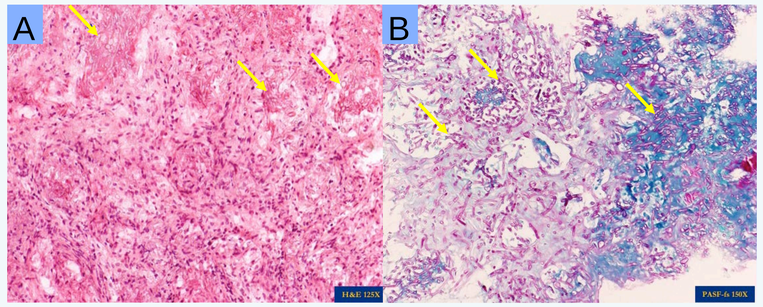

(A) Partial tissue necrosis with fungus on H&E
(B) With Aspergillus type fungus on PASF-fs

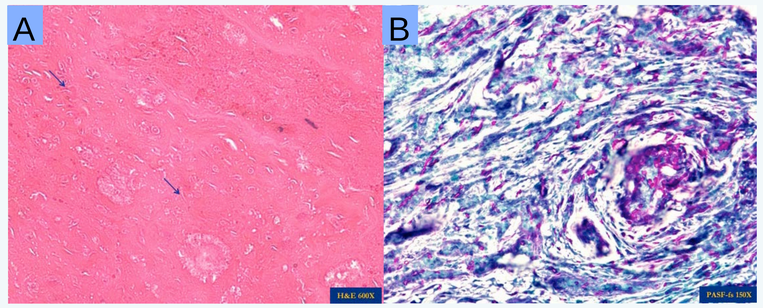

(A) Thick amorphous necrosis with indistinct fungus on H&E
(B) But abundant Aspergillus type fungus evident on PASF-fs

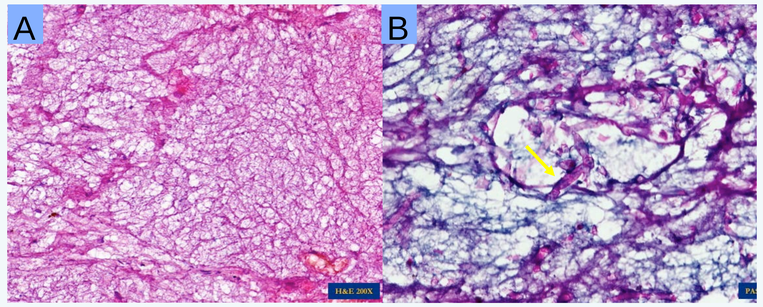

(A) Lacy network of necrosis not recognizable as tissue on H&E
(B) But containing Mucor type fungus on PASF-fs

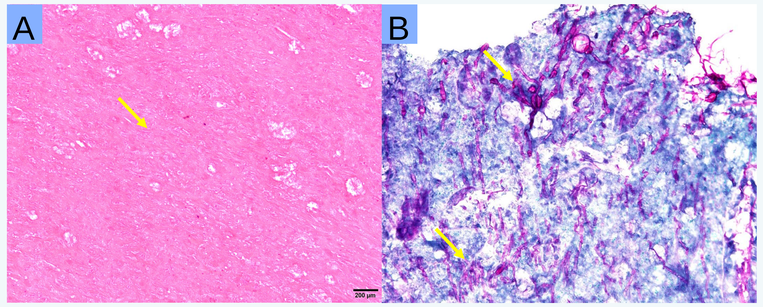

(A) Necrosis with fungal hyphae barely discernable on H&E
(B) PASF-fs was done at the time of FS not stained over a previous H&E. It clearly shows the presence of fungus.

Methods

A retrospective review of all biopsies with FS for suspected AIFRS at our institution from 2006 to 2016 identified 215 specimens (51 positive and 164 negative). Rapid biopsy interpretation of hematoxylin and eosin (H&E) stained FS was followed by the final diagnosis after routine processing and Grocott Methenamine Silver stains for fungus. Original FS slides stained retrospectively using a PASF-fs method for frozen tissue to identify fungus was compared to the original FS interpretations and final diagnoses.

Results

On H&E FS analysis, 9 false negative diagnoses were made. The addition of rapid PASF-fs was able to identify fungus on 6 of the 9 false negative slides. The 3 remaining false negatives displayed no fungus due to technical error (inadequate biopsy or inadequate sectioning).

The sensitivity and specificity of FS with H&E staining for the diagnosis of AIFRS was 81.63% and 96.44% respectively, while including the rapid PASF-fs staining they increased to 93.87% and 100%.

Conclusions

1) The use of frozen section with rapid PASF-fs stain following biopsy for suspected AIFRS provides a means to obtain a rapid and accurate diagnosis of AIFRS. This allows for shorter times to surgery, which will improve outcomes for patients with AIFRS.

2) The histologic diagnosis of AIFRS requires identifying fungus invading tissues with necrosis. Communicating the clinical presence of ischemia or necrosis to the pathologist can assist in interpretation, as other changes can mimic necrosis on H&E. Communication and PASF-fs staining then can significantly reduce the barriers to rapid pathologic diagnosis.