

ABSTRACT

Objective: We report the case of a patient with debilitating dysphagia, velopharyngeal insufficiency and hypernasal speech following staged TORS resection of simultaneous, bilateral squamous cell carcinoma of the palatine tonsils that subsequently resolved after reconstruction with palatoplasty and pharyngeal flap repair

Study Design: Case Study

Methods: Retrospective review of a case record at a tertiary care medical center. Literature review using a PubMed search for bilateral tonsillar carcinoma, dysphagia, and velopharyngeal insufficiency.

Results: We present a 68 year-old female with bilateral palatine squamous cell carcinoma. She presented with biopsy-proven p16 positive disease in the right tonsil and underwent staged transoral robotic resection and bilateral neck dissection. Post-operatively she dysphagia, velopharyngeal insufficiency, and severe hypernasal speech. At three months post-resection, she underwent palatoplasty with posterior pharyngeal flap. She was seen reliably in follow-up with gradual resolution of post-surgical symptoms. She is currently three years post-op, remains disease free with no voicing or swallowing complaints.

Conclusions: In the appropriately selected patient, treatment of simultaneous, bilateral squamous cell carcinoma of the palatine tonsil with staged TORS resection is a viable option despite the risk of dysphagia, velopharyngeal insufficiency, and hypernasal speech, which can be corrected with palatoplasty utilizing a posterior pharyngeal flap.

REFERENCES

1. Rajenderkumar D, Chan KK, Hayward KA, McRae RD. Bilateral synchronous tonsillar carcinoma. *J Laryngol Otol.* 1999;113(3):255-257.
2. Mowaleed D, Qayyum A, Price T, Sharma A, Mahendran S. Bilateral synchronous tonsillar carcinoma: a case series and review of the literature. *Eur Arch Otorhinolaryngol.* 2012;269(1):255-259. doi:10.1007/s00405-011-1586-y.
3. Roesser MM, Alon EE, Olsen KD, Moore EJ, Manduch M, Schembri Wismayer DJ. Synchronous Bilateral Tonsil Squamous Cell Carcinoma. *The Laryngoscope.* 2010;120(S4):S181-S181. doi:10.1002/lary.21645.
4. Patel AB, Hinni ML, Pollei TR, Hayden RE, Moore EJ. Severe prolonged dysphagia following transoral resection of bilateral synchronous tonsillar carcinoma. *Eur Arch Otorhinolaryngol.* 2015;272(11):3585-3591. doi:10.1007/s00405-015-3540-x.
5. Erkal HS, Mendenhall WM, Amdur RJ, Villaret DB, Stringer SP. Synchronous and metachronous squamous cell carcinomas of the head and neck mucosal sites. *J Clin Oncol Off J Am Soc Clin Oncol.* 2001;19(5):1358-1362.
6. Dawe N, Patterson J, O'Hara J. Functional swallowing outcomes following treatment for oropharyngeal carcinoma: a systematic review of the evidence comparing trans-oral surgery versus non-surgical management. *Clin Otolaryngol.* 2016;41(4):371-385. doi:10.1111/coa.12526.

CONTACT

James M. Hamilton, MD
Thomas Jefferson University Hospital
Email: james.hamilton@jefferson.edu
Phone: 215.519.1296

INTRODUCTION

Squamous cell carcinoma (SCC) of the palatine tonsil is the third most common malignancy in the H&N and the most common subsite of the oropharynx (OP) for malignant neoplasms.^{1,2} Typical presentation is a unilateral OP mass or a mass in the ipsilateral neck indicating a metastatic lymph node.³ Established malignancy in one tonsil carries a small but significant risk of an occult contralateral tumor and simultaneous discontinuous disease does occur rarely.^{2,4} Synchronous cancers in the head and neck region are well documented, having been shown to occur in approximately 7% of patients⁵ but synchronous bilateral tonsillar SCC remains rare with less than 20 cases reported over the past 15 years.

Treatment for SCC of the tonsillar fossa includes any combination of surgery, radiotherapy and chemotherapy as determined by disease stage and functional status. There has been a significant movement toward minimally invasive surgical techniques and approaches including transoral robotic surgery (TORS) as surgeons widen the repertoire of operations that can be performed with the surgical robot. This approach offers multiple advantages including shorter operating time, preservation of speech and swallowing, decreased hospital stay and decreased patient morbidity and mortality. TORS has shown benefit in management of unilateral OP or tonsillar SCC, however the complication of prolonged, severe dysphagia noted after TORS in patients with bilateral tonsillar carcinoma when compared to standard bilateral palatine tonsillectomy has not been widely described. Regarding treatment of synchronous bilateral tonsillar SCC, a recent report recommends proceeding cautiously with primary surgical intervention as the incidence of dysphagia may be as high as 75%.⁴

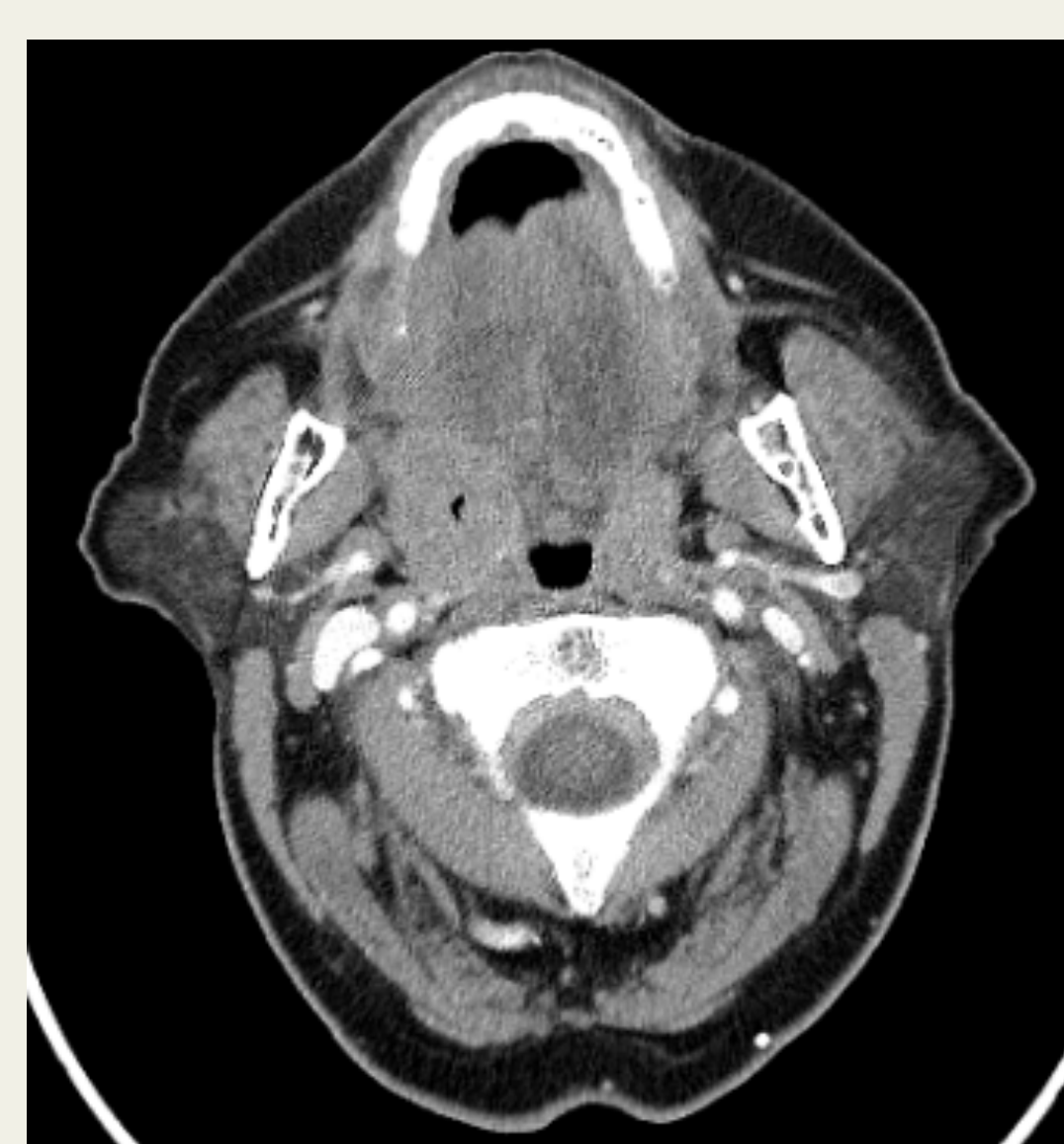


Figure 1. Contrast CT showing 4.0 x 2.1 x 1.6 cm right tonsil mass with on cervical adenopathy

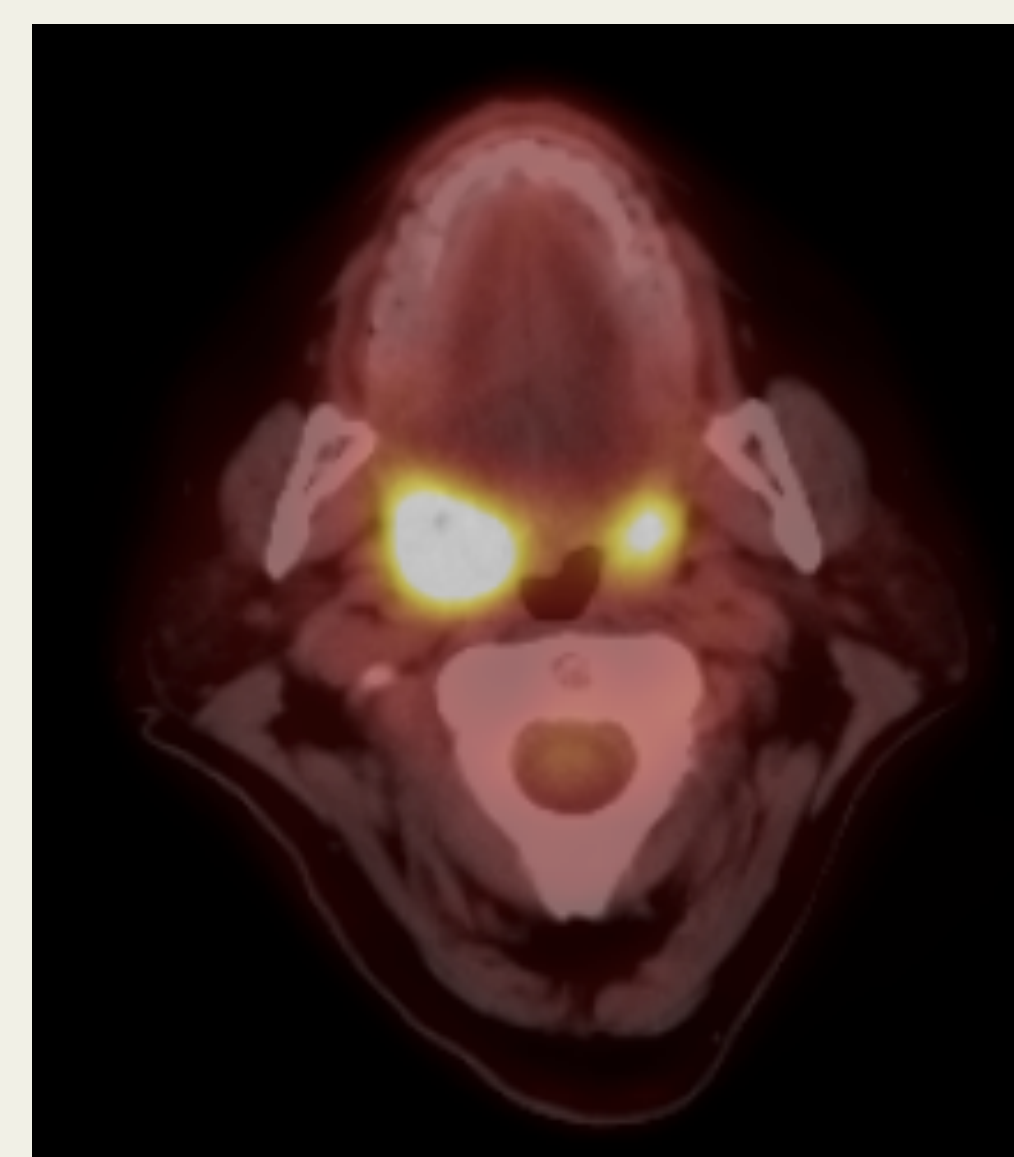

Figure 2. PET/CT showing hypermetabolic right tonsil (SUV 19) and Hypermetabolic left tonsil (SUV 9)

CASE PRESENTATION

A 68 year-old female presented with biopsy-proven p16 positive disease in the right tonsil and underwent TORS radical resection and buccal fat graft repair of palatal defect. (Figure 1) Biopsy of the left tonsil revealed simultaneous squamous cell carcinoma in situ. Post-operatively, she complained of hypernasal speech. Three weeks later she underwent TORS radical tonsillectomy on the left. On follow-up, she continued to experience dysphagia, velopharyngeal insufficiency, and hypernasality so severe that it limited her social interaction. Exam revealed scarring in her tonsillar fossae causing restricted movement of her palate and lateral and

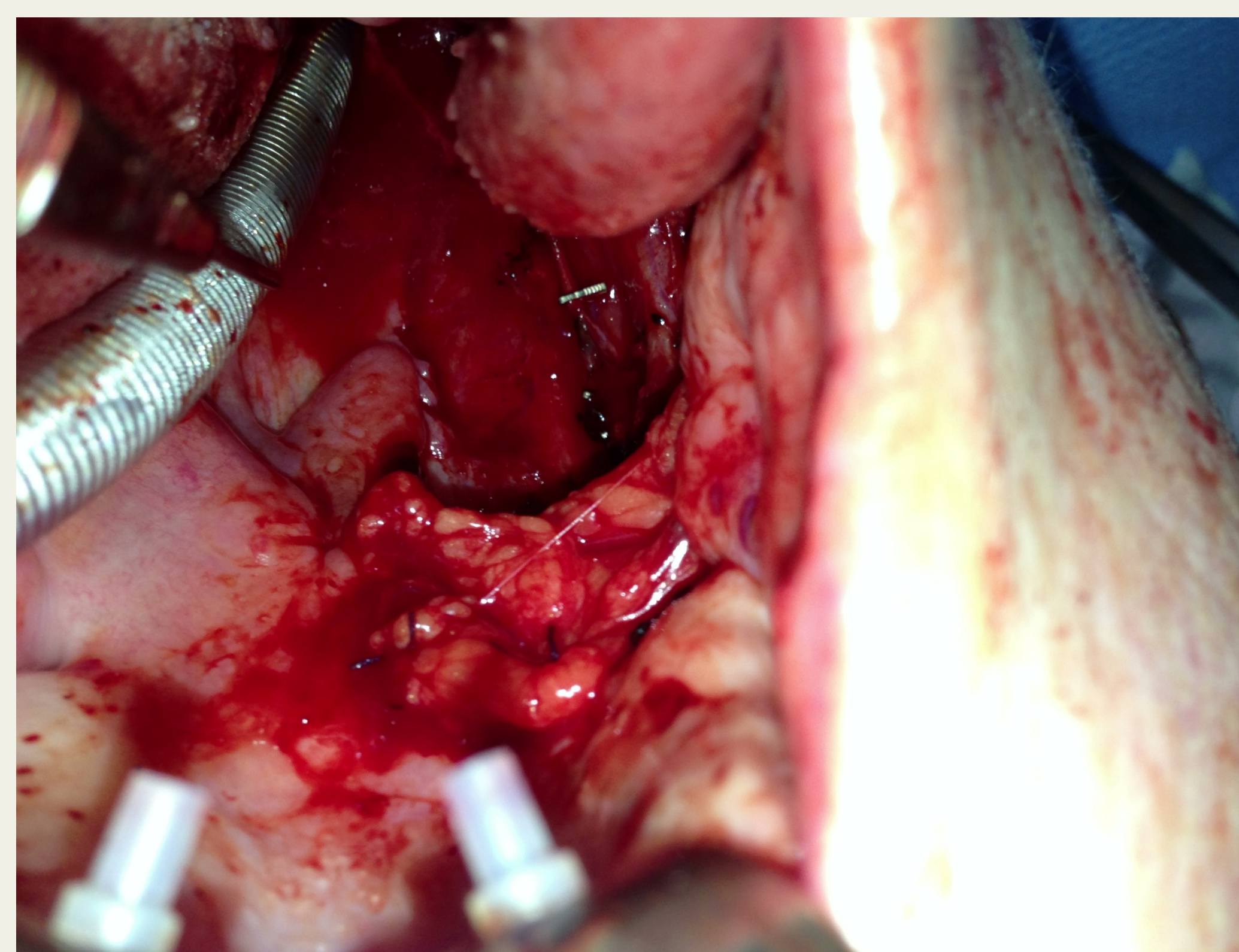


Figure 3. TORS resection of the right tonsil and biopsy of left tonsil; Buccal fat graft performed for palatal defect

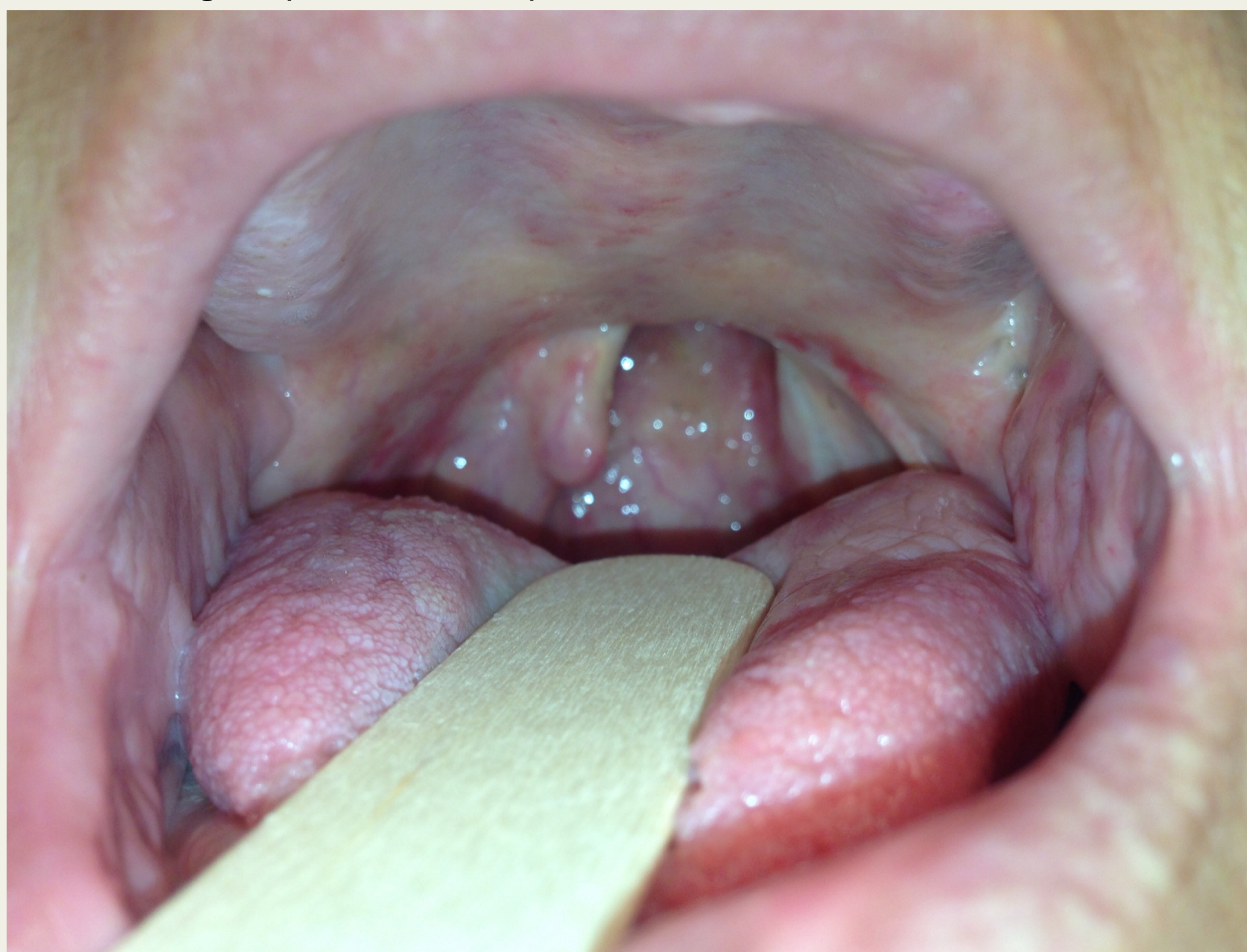

Figure 4. Scarring of bilateral tonsillar fossae restricting movement of soft palate and pharyngeal walls and increased nasopharyngeal diameter

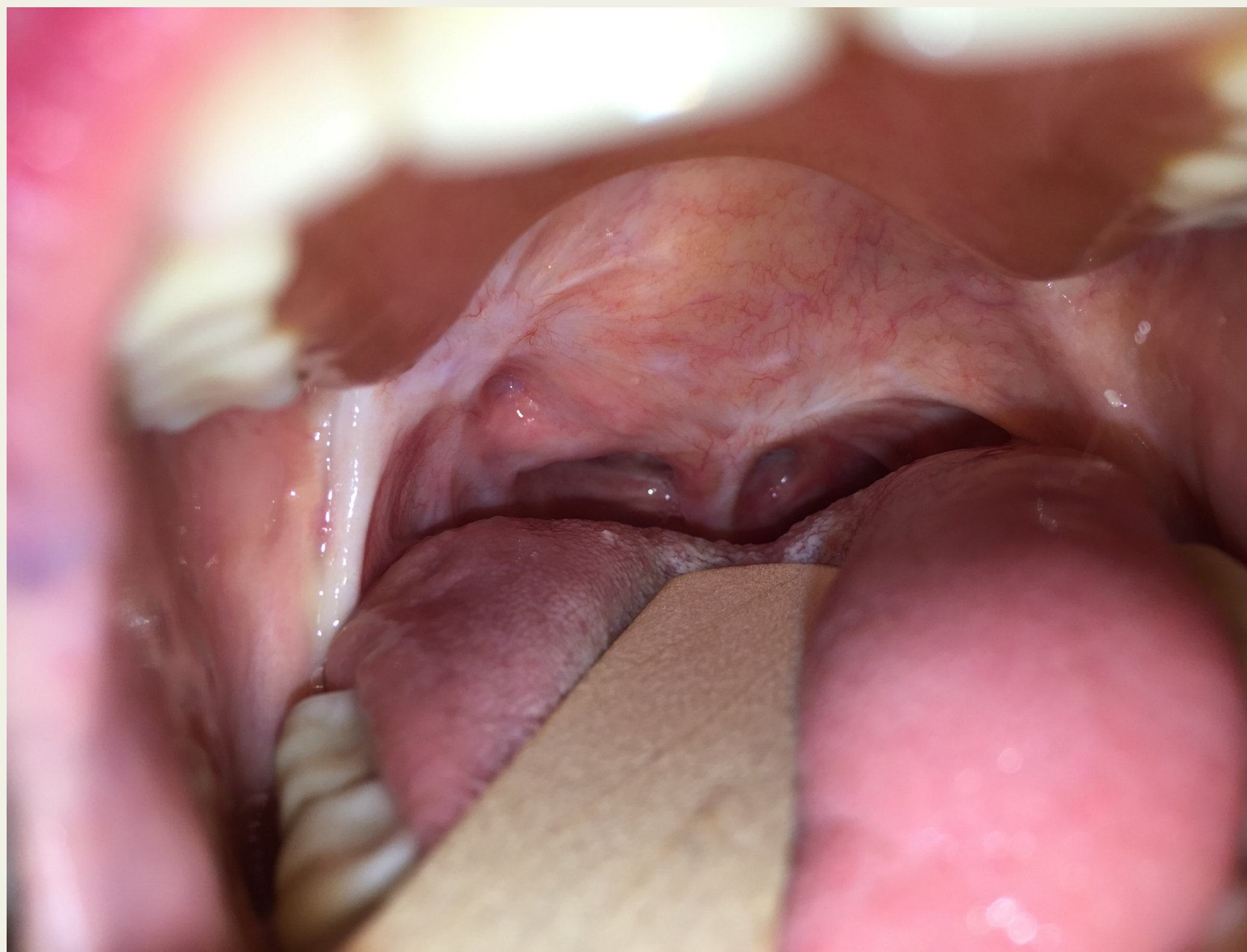


Figure 5. Well-healed midline posterior pharyngeal flap with patent 1.5 cm ports bilaterally

pharyngeal walls and an enlarged AP diameter of the nasopharynx. (Figure 2) At three months post-resection, she underwent palatoplasty with posterior pharyngeal flap. The scarred palate was initially released from the lateral pharynx. Next, a superiorly-based flap was elevated off the prevertebral fascia. The flap was inset into the open soft palate and the palate closed in layers thus sandwiching the flap and completely closing the pharynx with the exception of two 1.5 cm side ports. (Figure 3) Post-operative week one she was tolerating liquids without nasal regurgitation. At three months, she reported near-normal voice. At six months, she was without dysphagia and had returned to her normal routine. She is currently three years post-op, remains disease free with no further voicing or swallowing complaints.

DISCUSSION

Given the rise in HPV-related SCC of the oropharynx and the fact that these patients tend to be younger, healthier, and non-smokers, the concept of survivorship following treatment has grown in importance and voice and swallowing outcomes are an increasing priority when planning treatment recommendations.⁶ TORS has demonstrated excellent oncologic and functional outcomes. However, surgical resection of bilateral disease comes with a risk of prolonged dysphagia. A 75% incidence of persistent dysphagia (FOSS stage V) in small series of patients who underwent transoral surgery for bilateral tonsillar carcinoma has been reported in the literature.⁴ A patient experiencing such an occurrence at our institution underwent incorporation of the well-described superiorly based posterior pharyngeal flap into the bilateral oropharyngeal defect with successful resolution of voicing and swallow function and 100% return to pre-operative functional status.

CONCLUSION

Staged TORS resection is a viable option for treatment of simultaneous bilateral SCC of the palatine tonsils despite the risk of dysphagia, velopharyngeal insufficiency, and hypernasal speech. In cases of successful disease eradication in which these sequelae occur, the well-described superiorly-based posterior pharyngeal flap can be used to successfully reconstruct the OP and return the patient to normal function.