Early Tissue Oxygenation Patterns as a Predictor of Pedicled Fasciocutaneous Flap Survival

Jefferson®
HOME OF SIDNEY KIMMEL MEDICAL COLLEGE

Lucas M Bryant, MD[1]; Edita Aksamitiene[1,2], PhD; Jan B Hoek[2], PhD; Edmund E Pribitkin[1], MD

[1] Dept. of Otolaryngology – Head & Neck Surgery, Division of Facial Plastic Surgery
[2] Dept. of Pathology, Anatomy & Cell Biology

Introduction

Objective: Assess early changes in tissue oxygenation in a pedicled fasciocutaneous flap using a rat model.

Overview: Local flaps are a mainstay in facial reconstructive efforts. They are used to treat a variety of cosmetic and functional deficits. Flap failure due to tissue ischemia can be a costly and time consuming event. Early recognition of tissue compromise may lead to better outcomes in recovery attempts.

Currently, the standard of care for monitoring of local tissue flaps is based on clinical assessment for signs of congestion, ischemia, or other. We developed a reproducible rat model using auto-controlled, bilateral abdominal fasciocutaneous advancement flaps (**BEAFAF**). The pedicle for the BEAFAF is the inferior epigastric artery. We used this model to identify markers in the early post-operative timeframe (1-2 days) which can accurately **predict the future fate of the flap.**

Methods

Forty-five 1 year old, male, Sprague-Dawley rats were used. An overview of the experiment design is shown below. (**Figure 1**). Bilateral fasciocutaneous flaps were designed on shaved and prepped rat abdomens as shown below. (**Figure 2**) The pedicle (inferior epigastric artery) was identified and spared. The contralateral pedicle was isolated and clipped. The distal end was removed, creating a tissue defect. Flaps were then advanced bilaterally and closed with absorbable suture.

Real time, *in vivo* tissue oxygenation levels (StO_2) were measured for both flaps using photoacoustic imaging and high resolution doppler ultrasonography. Measurements were made pre-operatively and 2 days postoperatively.

Flaps were evaluated for necrosis on postoperative day 7 using planimetric analysis of standardized photos. Flaps were divided into three groups: survived, partial failure, and complete failure. Partial failure was defined as less than 50% necrosis, whereas total failure was defined as greater than 50% necrosis of total flap area. (**Figure 3**)

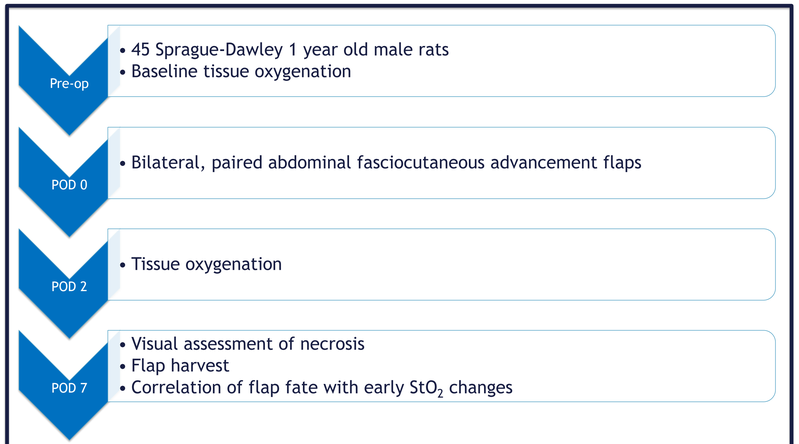

Figure 1. Timeline of experimental interventions

Results

Tissue oxygenation patterns on post-op day 2 correlated with subsequent flap necrosis or survival. In flaps developing visible necrosis by gross examination on day 7, there was an average decrease of tissue oxygenation levels of 29%. In flaps which ultimately survived, there was an average increase in tissue oxygenation levels of 26%.

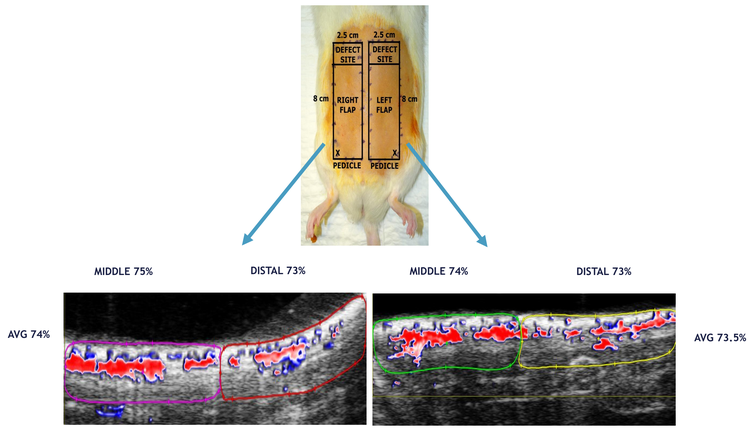

Figure 2. Design of bilateral abdominal fasciocutaneous advancement flaps using inferior epigastric vessels as pedicle. *In vivo* high frequency photoacoustic ultrasonography measurements of total oxygenation is shown on bottom of figure.

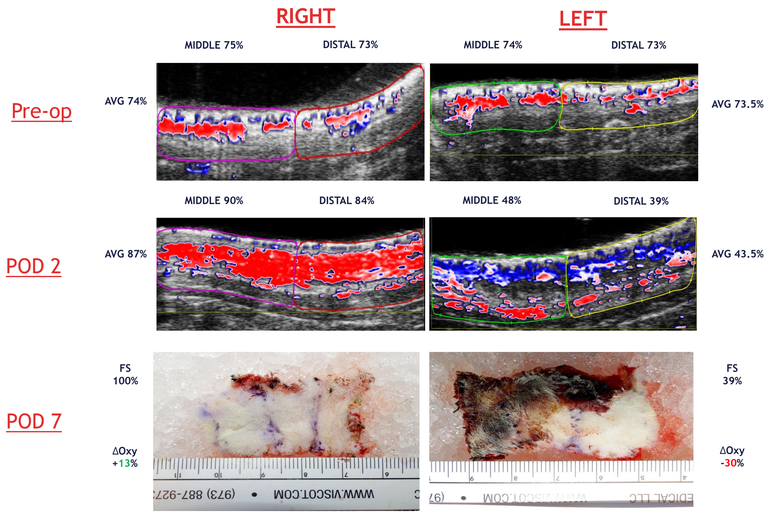

Figure 3. Example tissue oxygenation changes and postop gross visualization of flap necrosis in single rat. Right side with complete flap survival, left side with partial failure (39% surface area necrosis)

Statistical analysis showed the $\Delta StO_2\%$ between Pre-op and POD 2 levels strongly correlated with future flap outcomes ($p < 0.001$). This is demonstrated graphically using a receiver operating characteristics (ROC) curve analysis. (**Figure 4**) While $\Delta StO_2\%$ was a very strong predictor of future flap fate, it failed to differentiate between partial and full flap failure.

Results (cont.)

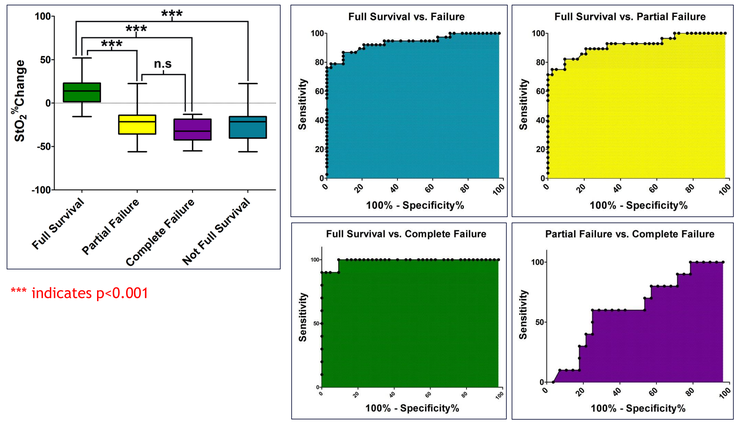

*** indicates p<0.001

Figure 4: Area under curve represents accuracy of test (ability to distinguish between groups). An area of 1 is a perfect test, whereas an area of 0.5 is a useless test. The ROC curves above demonstrate that the oxygenation changes observed reliably differentiate between survival and failed flaps (partial and complete failure), but do not reliably differentiate between partial and complete failure cases.

Discussion

Flaps are a frequently used method of reconstruction in otolaryngology patients. While they can be used to successfully obviate a devastating functional and cosmetic defect, flap failure can be equally devastating. Failure often results in many more clinic and/or surgical visits. Additional operative procedures for both debridement and reconstruction are often required. Early identification of flap compromise may allow for faster intervention and subsequent flap rescue.

The bilateral design of this flap model allows each rat to serve as its own control, eliminating inter-rat variability. Although this experiment clipped the pedicle artery and vein, this model could easily be modified to replicate venous congestion or arterial occlusion only.

Successful study of vascular compromise requires an easily reproducible model, which we created. This can be used in future studies to assess pharmacologic agents which may effect flap rescue. It may also be used to better understand both intrinsic and extrinsic properties which may affect flap outcomes.

Conclusions

- Bilateral epigastric artery pedicled fasciocutaneous advancement flaps (BEAFAF) in a rat model provide a reliable and repeatable model for assessment of ischemic tissue insult.
- Early post-operative changes in tissue oxygenation may serve as a predictor of future tissue fate.

Acknowledgements

Maria Stanczak, MS, RDMS, RVT; John Eisenbrey, PhD. (Thomas Jefferson University Hospital, Department of Radiology)