Jefferson
Philadelphia University + Thomas Jefferson University
HOME OF SIDNEY KIMMEL MEDICAL COLLEGE

Sinonasal Complications Following Orbitomaxillary Free Flap Reconstruction

Bovenzi CD, Godovchik J, Ciolek P, Fastenberg J, Rosen M, Curry JM, Heffelfinger R
Department of Otolaryngology- Head & Neck Surgery, Thomas Jefferson University Hospital

Abstract

Introduction: Reconstruction of large midface defects presents unique challenges to head and neck reconstructive surgeons as tissue bulk needed to appropriately fill a defect also has the potential to obstruct normal sinonasal anatomy with resulting morbidity. To date, there is a paucity of data analyzing the incidence and management of sinonasal complications seen after orbitomaxillary free flap reconstruction.

Methods: In a retrospective review, consecutive cases of maxillectomy with or without orbital exenteration with concurrent free flap reconstruction performed at a single institution between 2014 and 2018 were reviewed. A range of pre and post-operative variables were analyzed.

Results: A total of 141 cases were identified. Of these, 9 patients (6.4%) required surgical treatment for sinonasal-related complications, including nasal obstruction (n=3), chronic rhinosinusitis (CRS) (n=3), and mucocele formation (n=5). Time to surgery ranged from 2 to 36 months and led to resolution of symptoms in all patients aside from one, who required a second surgery for refractory CRS. The type of free flap did not significantly impact the rate of sinonasal complications requiring operative intervention. However, patients with a greater pre-reconstructive defect based on Brown classification had a significantly greater risk of sinonasal complications requiring operative intervention (median classification 4a vs. 2c, p=0.002).

Conclusions: Patients that require orbitomaxillary free flap reconstruction, especially those with larger defects requiring greater tissue bulk, are at risk of post-operative sinonasal complications, including mucocele formation. These complications can be appropriately managed surgically. The identified incidence belabors the importance of appropriate monitoring for sinonasal complications in both the immediate and more extended post-operative period. Furthermore, these findings may prompt consideration of techniques to prevent functional obstruction in select circumstances, such as the use of frontal sinus stents.

Introduction

The major goals of midface reconstruction are to provide adequate support of the orbit and facial skin, sealing the oral cavity from the nasal cavity, and restoring proper dental occlusion. (Santamaria & Cordeiro, 2006). Flaps therefore require sufficient bulk to achieve these goals, but such mass has the potential to obstruct and distort normal sinonasal anatomy, causing morbidity and even requiring additional surgical intervention. Currently, there are small data sets evaluating these patients complications in the postoperative period (Murphy et al., 2015) but there is a paucity of data regarding the incidence, character, and management of sinonasal complications encountered after orbitomaxillary free flap reconstructions.

Methods

A retrospective review of all free flap cases performed at Thomas Jefferson University Hospital from 2014 through 2018. Cases that involved maxillectomy with or without orbital exenteration were identified. Imaging was reviewed and patient defects were classified according to the modified Brown Classification for maxillectomy defects (Brown and Shaw, 2010). A chart review was conducted to determine reasons patients required a return to the operating room and patients who underwent procedures for sinonasal complaints were further studied with an in-depth review of operative reports and further follow up visits.

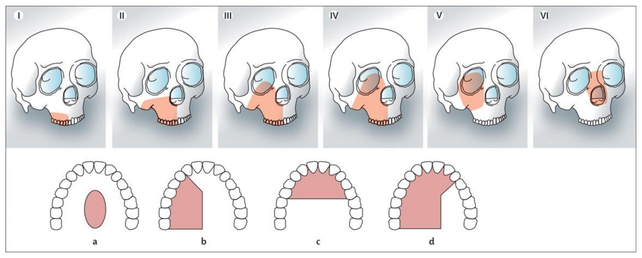

Figure 1. Modified Brown Classification for Orbital and Maxillectomy Defects

Results

Patient	Age	Sex	Brown Classification	Type of Free Flap	Time since Original Surgery (months)	Reason for Reoperation	Sinonasal Subsites Affected and Treated
1	33	F	2b	OCRFFF	12	Mucocele	E, M
2	69	F	3b	Scapula, OCRFFF	10	Mucocele, wound breakdown	F (obliteration), RFFF for maxillary defect
3	70	M	5	ALTFF	19	Mucocele	F (with stent), E, M, S
4	68	M	6	ALTFF	16	Mucocele	E, M, S
5	67	M	4a	ALTFF	7	Mucocele	E, M, S
6	49	F	3b	Scapula	9	Chronic Sinusitis & Obstruction	F, E, M, S
7	86	M	5	ALTFF	8	Chronic Sinusitis & Repeat Biopsy	F, E, M, septal biopsy
8	57	F	5	OCRFFF	2	Obstruction & Wound Breakdown	NC (flap debulking, synechiae removal)
9	54	M	3a	ALTFF	36	Chronic Sinusitis & Obstruction	E, M, NC (flap debulking)

Table 1. Sinonasal Causes for Reoperation Following Orbitomaxillary Free Flap Reconstruction

There were 9 patients who underwent reoperation due to sinonasal complications which were related to mucocele formation, chronic sinusitis, and nasal valve obstruction.

ALTFF: anterolateral thigh free flap; OCRFFF: osteocutaneous radial forearm free flap, F: frontal sinuses; E: ethmoid sinuses; M: maxillary sinuses, S: sphenoid sinuses, NC: nasal cavity; PMFF: paramedian forehead flap

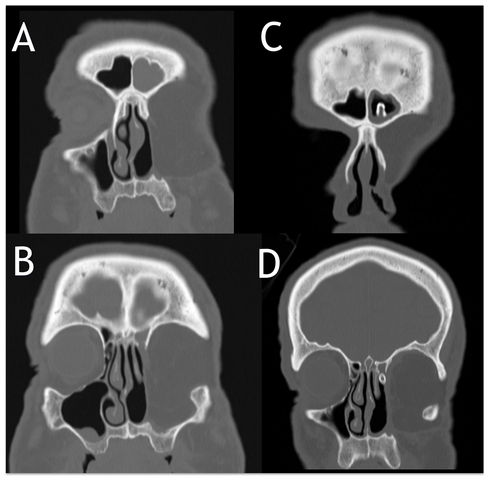

Figure 2. Example of Frontal Sinus Mucocele Development and Treatment

Figures 2A &B demonstrate free flap obstruction of the frontal outflow tract resulting in mucocele formation. Figures 2C & D reveal a possible treatment option for these patients of frontal sinusotomy with stent placement

Results (continued)

A total of 141 cases were identified. 54 patients required re-operation (38.3%). 9 Patients (6.4%) required reoperation for sinonasal complaints including Mucocele (n=5, 3.5%), Chronic Sinusitis (n=3, 2.1%), and Nasal Valve Obstruction (n=3, 2.1%). These patients were treated with functional endoscopic sinus surgery to allow for adequate drainage of the sinus cavities adjacent to the free flap reconstruction (Table 1). Nasal valve obstruction was treated with flap debulking and removal of synechiae (Table 1). These complications were addressed between 2 months and 36 months after the original free flap reconstruction.

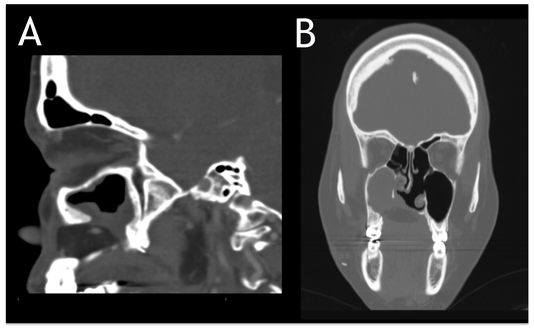

Figure 3. Example of Chronic Maxillary Sinusitis Development At Site of Free Flap Reconstruction

Figures 3 A & B demonstrate the radiographic evidence of chronic sinusitis and maxillary sinus opacification in the region of former free flap reconstruction with the tissue density differentiating healthy flap bulk from mucosal thickening and purulent debris in the maxillary sinus.

Discussion

- Sinonasal complications can occur with many free flap types in midface reconstruction
- Endoscopic sinus surgery, delayed flap debulking, and use of adjunctive devices such as frontal sinus stents may mitigate these sinonasal complications
- Care should be made during flap inlay to preserve native sinonasal outflow tracts if possible as chronic sinusitis, nasal valve obstruction, and mucoceles can develop
- Performing sinus surgery at the time of reconstruction may potentially prevent sinonasal complications

References

- Smolka, W. & Izuka, T. (2005). Surgical reconstruction of maxilla and midface: Clinical outcome and factors relating to postoperative complications. Journal of Cranio-Maxillofacial Surgery, 33, 1-7.
- Santamaria, E. & Cordeiro, P. G. (2006). Reconstruction of maxillectomy and midfacial defects with free tissue transfer. Journal of SurgicalOncology,94, 522–531.
- Murphy, J., Isaiah A., Wolf, J.S., Lubek, J.E. (2015). Quality of Life Factors and Survival After Total or Extended Maxillectomy for Sinonasal Malignancies. J Oral Maxillofac Surg, 73, 759-763.
- Brown, J.S. & Shaw, R.J. (2010). Reconstruction of the maxilla and midface: introducing a new classification. Lancet Oncology, 11, 1001-8.