


# PET Positive Warthin's Tumor and False Positive FNA with Known Tongue Cancer and Bilateral Cervical Node Metastasis



Ryan C. Borek, MD; Adam C. Kaufman, MD, PhD; Kim O. Learned, MD; Michael D. Feldman, MD; Laurie A. Loevner, MD; Bert W. O'Malley, MD; Christopher H. Rassekh, MD  
Department of Otorhinolaryngology: Head & Neck Surgery, University of Pennsylvania

## Abstract

**Objectives:** Warthin's tumors have high affinity for FDG mimicking malignancy. This can result in a false positive diagnosis of parotid or neck cancer, which can be particularly confusing in smokers with known squamous cell carcinoma of the upper aerodigestive tract. Further workup including fine needle aspiration and/or technecium-99 scintigraphy is reliable for clarifying the diagnosis. We present a case of an exceptional patient with carcinoma of the tongue and bilateral cervical metastasis who also had a positive FNA in a contralateral parotid mass.

**Study Design:** Case report.

**Methods:** A 62 year old male smoker presented with a p16+ ventral tongue carcinoma and clinically positive ipsilateral cervical metastases. Contralateral nodal metastasis and parotid mass were identified on PET/CT scan. FNA of the parotid was interpreted as carcinoma.

**Results:** The patient underwent a hemiglossectomy and neck dissection. The parotid mass appeared to be oval shaped and well encapsulated. A local excision of the mass was performed and frozen section pathology confirmed Warthin's tumor.

**Conclusions:** Warthin's tumors with PET/CT positivity can present a diagnostic dilemma in patients with known head/neck malignancy. This unusual case of concern for false positive FNA was potentially even more confusing but was managed conservatively. A false positive needle biopsy was suspected and parotidectomy was avoided in this setting. Understanding this presentation can minimize morbidity of a benign disease and not delay treatment of a malignant condition.

## Introduction

Warthin's tumors have high affinity for FDG mimicking malignancy resulting in a false positive diagnosis of parotid or neck cancer, which can be particularly confusing in smokers with known squamous cell carcinoma of the upper aerodigestive tract. Further workup including fine needle aspiration and/or technecium-99 scintigraphy can be reliable for clarifying the diagnosis. We describe a case of an exceptional patient with carcinoma of the tongue and bilateral cervical metastasis who also had a positive FNA in the evaluation of a contralateral parotid mass.

## Case Report

A 62-year-old male with extensive smoking history and current alcohol use presented with left sided otalgia and left sided oral pain for one year. A biopsy of a left sided ventral tongue lesion was performed and identified a p16+ squamous cell carcinoma. An MRI was done showing the tongue mass along with concern of a contralateral (right) sided parotid tail mass (Figure 1). A PET/CT scan was performed and demonstrated the presenting tongue lesion along with an FDG avid lesion, 1.6 x 1.1 cm, in the inferior region of the right parotid with a maximum SUV of 6.6. (Figure 2). An ultrasound guided FNA biopsy of the parotid mass was performed and preliminary cytology demonstrated carcinoma. Final pathology of the FNA demonstrated squamous cell carcinoma in a background of extensive necrosis and lymphocytes. The patient was presented at multi-disciplinary tumor board for treatment planning.

The patient underwent resection of the ventral tongue cancer with left selective neck dissection and free flap reconstruction. Evaluation of the right parotid mass intra-operatively demonstrated a reddish-brown/tan, oval shaped, well encapsulated lesion. An excision of the mass and selective right level II neck dissection was performed. Frozen pathology demonstrated a Warthin's tumor and so a superficial parotidectomy was not undertaken.

Final pathology demonstrated a right level IIa node with metastatic keratinizing squamous cell carcinoma with evidence of a FNA needle tract, along with a 1.2 x 1.1 x 0.4 cm brown-tan mass with a potentially cystic appearance positive for Warthin's tumor. The patient successfully underwent post-operative radiation for his T2N2cM0 p16+ left sided ventral tongue squamous cell carcinoma. Follow up PET scanning 6 months later demonstrated no evidence of head/neck pathology.

## Discussion

Warthin's tumors (papillary cystadenoma lymphomatosum) most often present in the parotid but can also present in the neck with 10% being bilateral. Warthin's tumors are known to be PET-Positive and the importance of understanding this feature in head/neck cancer patients has been described<sup>1,2</sup>. When this diagnostic dilemma occurs, one can consider FNA, ultrasound guided FNA, or Tc-99m pertechnetate salivary gland scintigraphy to further elucidate a diagnosis.

A preoperative ultrasound guided FNA was reportedly performed on the parotid tail mass (Figure 3), and initially read as squamous cell carcinoma. (Figure 4) During our write-up, analysis of the pathologic specimens demonstrated evidence that the FNA was performed on a right sided level IIa node rather than the Warthin's tumor. Figure 5 demonstrates evidence of a FNA needle tract in the node. Therefore, the initial false positive was not a true representation of the parotid mass, rather a false targeted FNA. For completion, Figure 6 displays the typical features of Warthin's tumor in our surgical specimen including the combination of epithelial and lymphoid components.

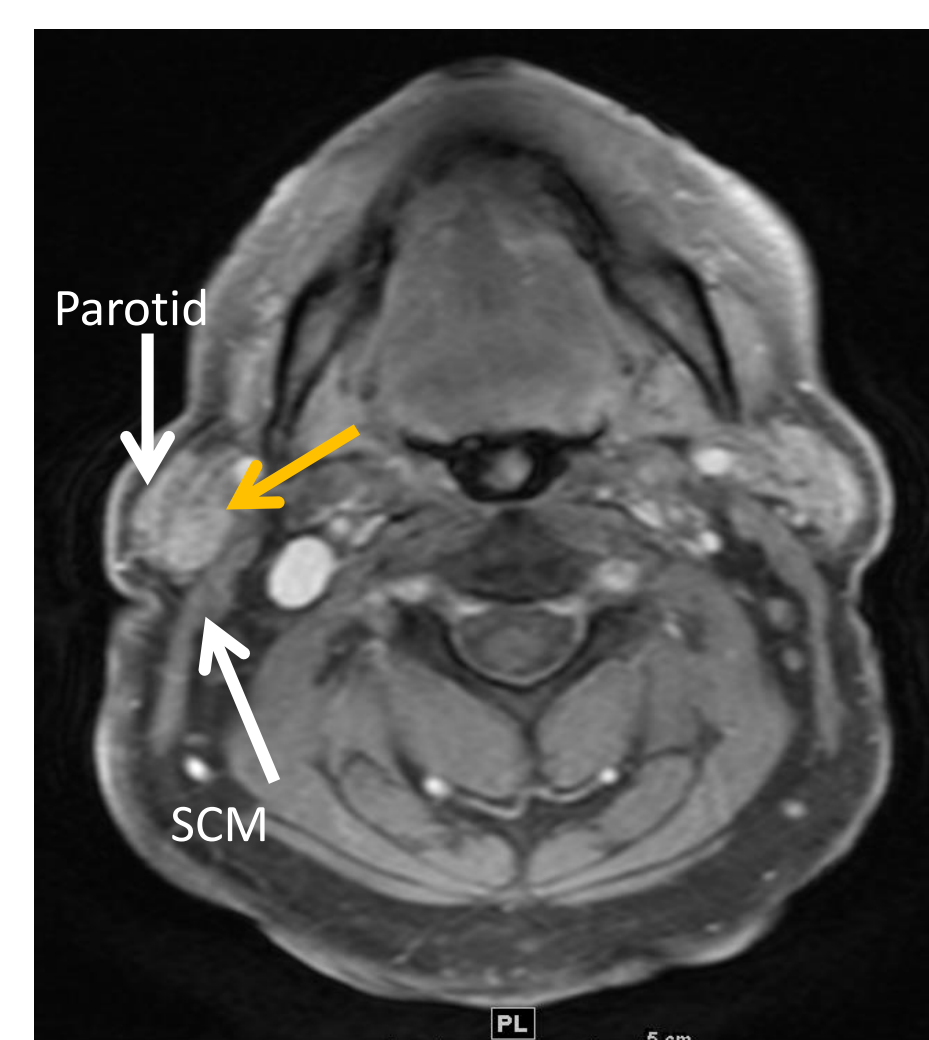


Figure 1. T1 MRI right parotid lesion

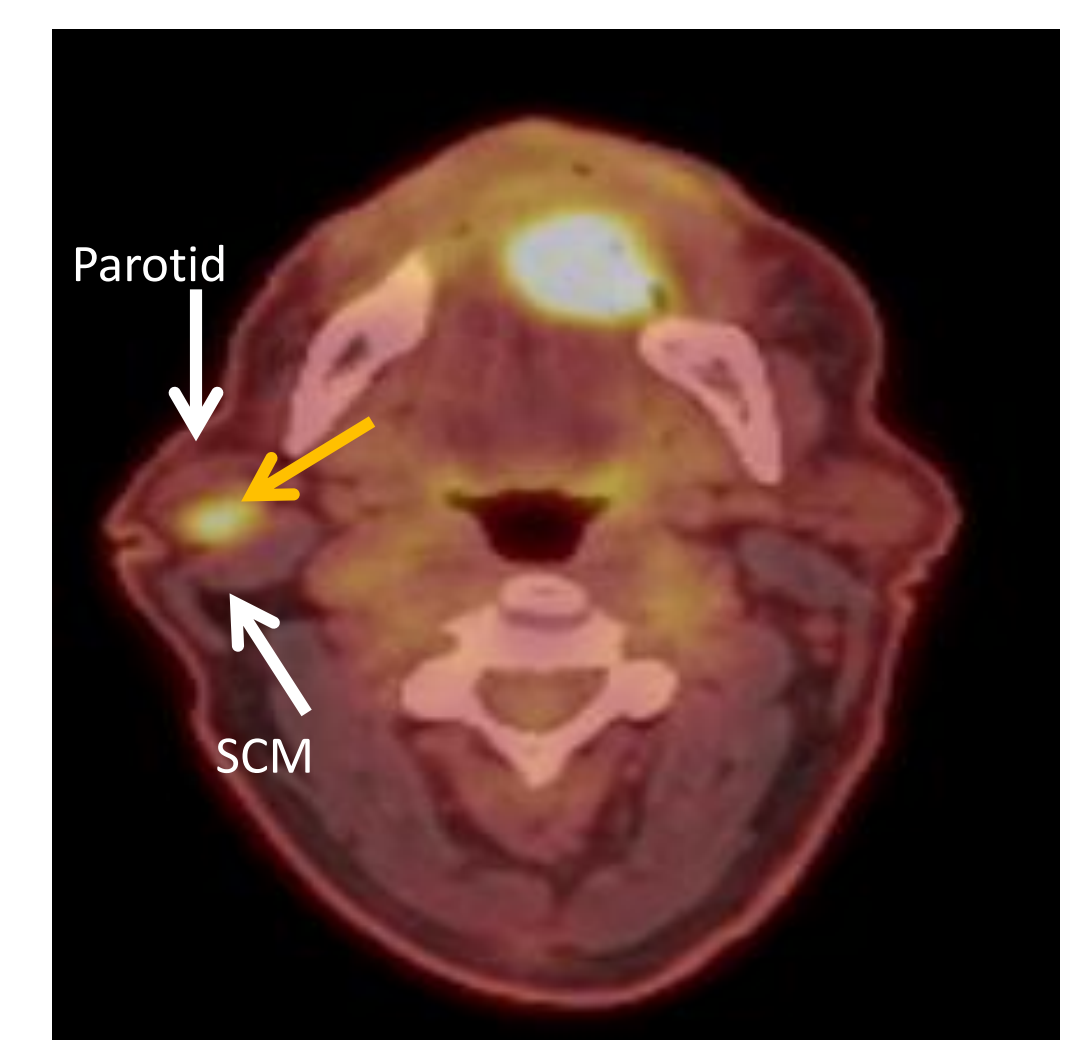


Figure 2. PET-CT demonstrating right parotid lesion (SUV 6.6).

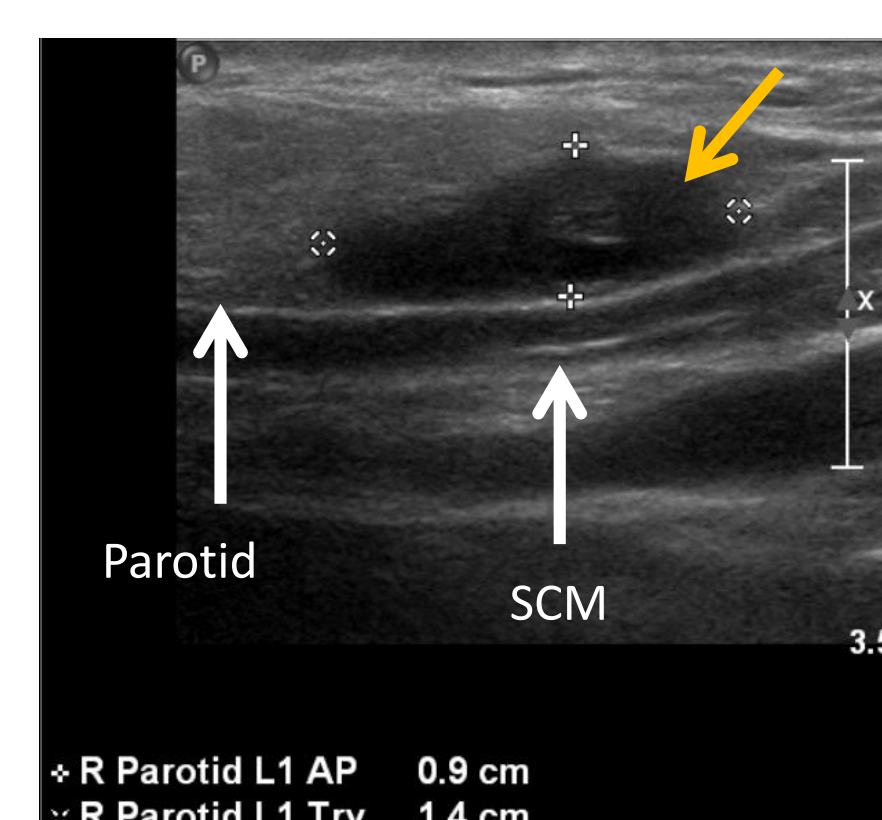


Figure 3. Ultrasound of right neck lesion

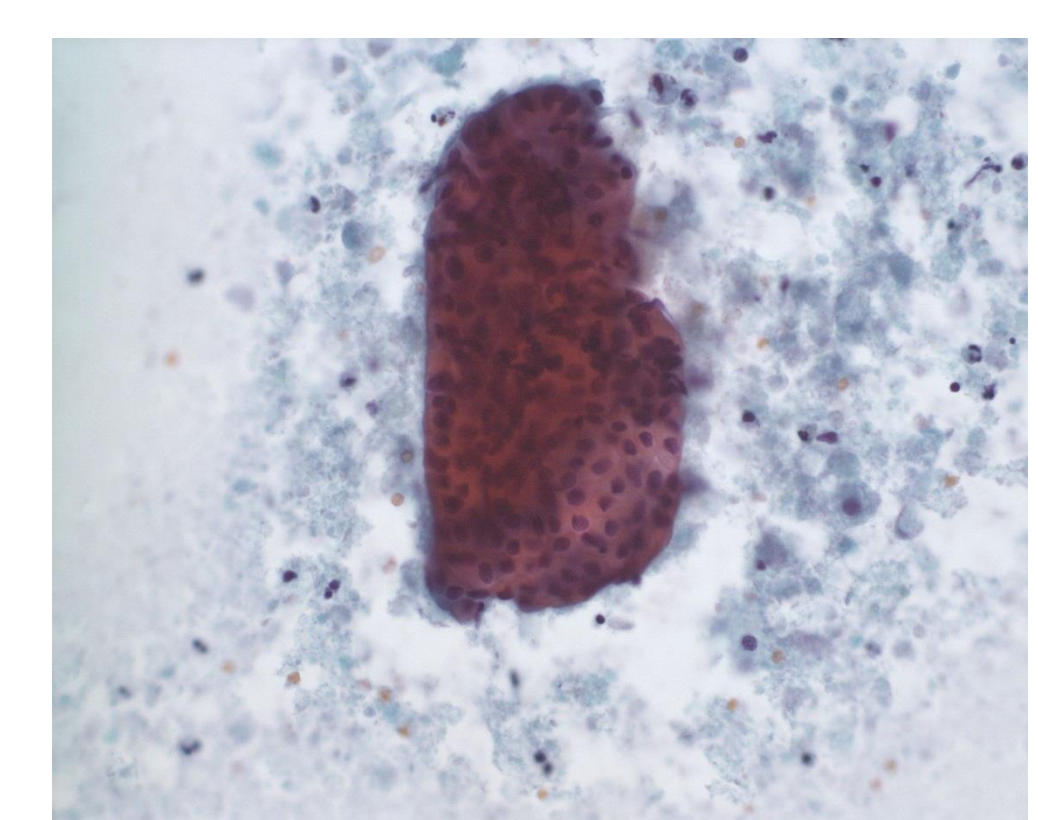


Figure 4. FNA of right neck lesion

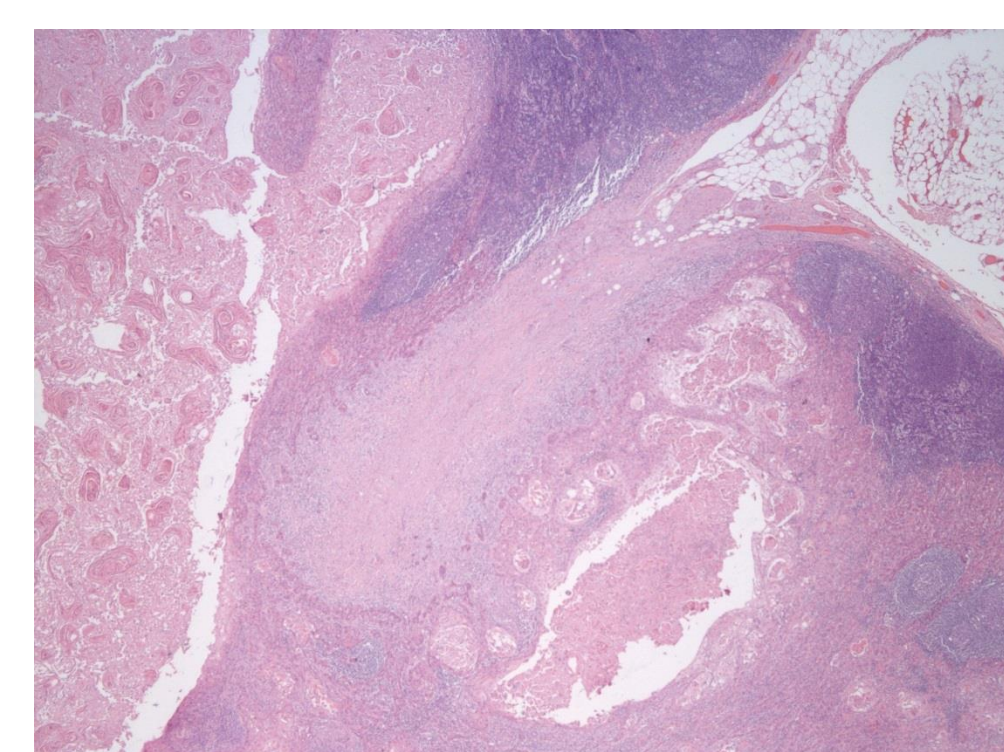


Figure 5. Right IIa node demonstrating FNA tract

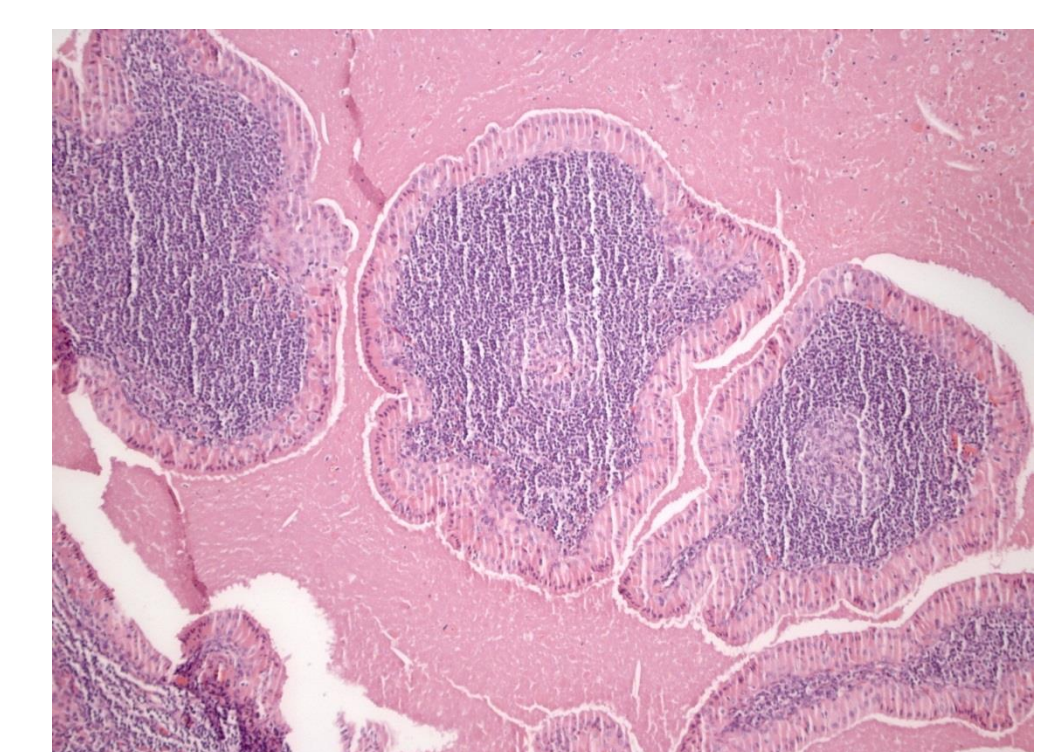


Figure 6. Final pathology: Warthin's Tumor

Discussion of the value of FNA cytology of parotid lesions is ongoing. A meta analysis in 2011 stated that a guideline on the clinical usefulness of FNA for parotid gland lesions could not be provided<sup>3</sup>. However, large single center trials demonstrated high accuracy in identifying malignancies with sensitivities of 85.7% and 75% and specificities of 99.5% and 95.1%<sup>4,5</sup>.

## Conclusions

Warthin's tumors with PET/CT positivity can present a diagnostic dilemma in patients with known head/neck malignancy. A false positive parotid needle biopsy was suspected and conservative management was undertaken resulting in avoidance of a parotidectomy. FNA remains a reliable method for evaluating PET positive parotid lesions. Understanding this presentation can minimize morbidity of a benign disease and not delay treatment of a malignant condition.

## Contact

Dr. Ryan C. Borek  
Department of Otorhinolaryngology Head and Neck Surgery  
University of Pennsylvania  
Email: ryan.borek@uphs.upenn.edu

## References

1. Rassekh CH, Cost JL, et al. Positron emission tomography in Warthin's tumor mimicking malignancy impacts the evaluation of head and neck patient. *American Journal of Otolaryngology*. 2015;36(2):259-263.
2. Uchida Y, Minoshima S, Kawata T, et al. Diagnostic value of FDG PET and salivary gland scintigraphy for parotid tumors. *Clinical nuclear medicine*. 2005;30(3):170-176.
3. Schmidt RL, Hall BJ, Wilson AR, Layfield LJ. A systematic review and meta-analysis of the diagnostic accuracy of fine-needle aspiration cytology for parotid gland lesions. *American Journal of Clinical Pathology*. 2011;136(1):45-59.
4. Tryggvason G, Gailey MP, Hulstein SL, et al. Accuracy of fine-needle aspiration and imaging in the preoperative workup of salivary gland mass lesions treated surgically. *The Laryngoscope*. 2013;123(1):158-163.
5. Feinstein AJ, Alonsa J, et al. Diagnostic Accuracy of Fine-Needle Aspiration for Parotid and Submandibular Gland Lesions. *Otolaryngol Head and Neck Surgery*. Epub Advance online publication. April 2016.